

Combining Poly-(ARD-Ribose) Polymerase and Programmed Cell Death Protein 1 Inhibition in a Patient with Esophagogastric Adenocarcinoma

Jule Cecilia Artzenroth^a Joseph Tintelnot^a Georg Martin Haag^b
Eray Gökkurt^{a, c} Johann Steffens^d Alexander Stein^{a, c}

^aUniversity Cancer Center Hamburg (UCCH), University Medical Center Hamburg-Eppendorf, Hamburg, Germany; ^bDepartment of Medical Oncology, National Center for Tumor Diseases, Heidelberg University Hospital, Heidelberg, Germany; ^cHämatologisch-Onkologische Praxis Eppendorf, Hamburg, Germany; ^dRadiologische Praxis am Israelitisches Krankenhaus, Hamburg, Germany

Established Facts

- There are limited therapeutic options for patients with metastatic, esophagogastric adenocarcinoma (EGA).
- Programmed cell death protein 1/L1 inhibitors have proven activity in patients with EGA in distinct subsets (high microsatellite instability [MSI-H], CPS >5/10) and/or in combination with chemotherapy.
- Poly-(ARD-Ribose) polymerase inhibitors are effective in tumors with a homolog recombination deficiency.

Novel Insights

- The combination of the poly-(ARD-Ribose) polymerase inhibitor olaparib and the programmed cell death protein 1 (PD-1) inhibitor pembrolizumab was applied in a patient with advanced esophagogastric adenocarcinoma with HDR mutation (RAD51C mutation) and high PD-L1 CPS (20) after progression on PD-L1 inhibition showing excellent tolerability and significant reduction of tumor mass.

Keywords

Esophagogastric adenocarcinoma · Programmed cell death protein 1/L1 inhibitors · Poly-(ARD-Ribose) polymerase inhibitors

Abstract

Introduction: Esophagogastric adenocarcinoma (EGA) is one of the leading causes of cancer-related mortality worldwide. Therapeutic options are limited for patients with recurrent or

metastatic disease. Targeted therapy may be a suitable treatment for selected patients, but its efficacy remains elusive.

Case Presentation: Here, a 52-year-old male patient with advanced EGA Siewert Type II shows a significant response to combination therapy with olaparib and pembrolizumab. After progression following first- and second-line therapy, including a programmed cell death ligand 1 (PD-L1) inhibitor, next-generation sequencing of a tumor sample was performed to identify possible molecular targets. A mutation in *RAD51C*, a member of the homology-directed repair (HDR) system, was

identified in addition to high PD-L1 expression. As a result, therapy with the poly-(ARD-Ribose) polymerase (PARP) inhibitor olaparib and the programmed cell death protein 1 (PD1)-inhibitor pembrolizumab was initiated. A durable partial response lasting for more than 17 months was observed. A second molecular profiling from a newly occurring subcutaneous metastasis showed a loss of *FGF10* but no fluctuations in the gene alteration of *RAD51C* and *SMARCA4*. Interestingly, the new lesion showed HER2-positivity (immunohistochemistry 3+ and fluorescence in situ hybridization [FISH]-positivity) in 30% of tumor cells. **Conclusion:** In this case, a long-lasting response to the combination of olaparib and pembrolizumab was observed despite previous treatment with a PD-L1 inhibitor. This case illustrates the need for further clinical trials to analyze the efficacy of PARP inhibitor combinations in EGA.

© 2023 S. Karger AG, Basel

Introduction

Globally, 1.7 million new cases of gastric and esophageal cancer occur each year, making them one of the leading causes of cancer-related mortality worldwide [1]. Approximately, 75% of patients with esophagogastric adenocarcinomas (EGA) will develop recurrent or metastatic disease at some point. For these patients, palliative systemic therapy with chemotherapy, ramucirumab, trastuzumab (for HER2-positive tumors), and checkpoint-inhibitors (for PD-L1-positive disease) is the mainstay of treatment [2–6]. In a phase II trial, the addition of a poly-(ARD-Ribose) polymerase (PARP) inhibitor (PARPi) to chemotherapy was shown to increase the overall survival compared to chemotherapy alone, particularly in the homolog recombination deficient (HRD) subgroup [7]. However, a phase III trial did not show a significant increase in overall survival with the combination of paclitaxel and olaparib [8]. In this case report, we present a patient with advanced EGA and HRD, who received a combination of olaparib and pembrolizumab, leading to a long-lasting partial response.

Case Report

The 52-year-old male patient was diagnosed with a poorly differentiated adenocarcinoma (intestinal type) of the esophagogastric junction Siewert Type II with stage cT3 N + M0. Initially, the patient received 4 cycles of neoadjuvant FLOT (5-fluorouracil, leucovorin, oxaliplatin, docetaxel) followed by esophagogastrectomy and adjuvant completion with another four cycles FLOT. During FLOT, the patient showed a partial response according to RECIST v1.1. Histological analysis of the initial biopsy obtained from the primary junction carcinoma revealed a negative HER2 status (IHC 0) and PD-L1 positivity (combined positive score [CPS] 20). The postsurgical tumor stage was ypT1 ypN2 L0 V0 R0 (regression grade II according to TU München classification.)

One month after the last cycle of adjuvant chemotherapy, the patient presented with a symptomatic global progress including peritoneal carcinosis and hepatic metastasis. In August 2020, the patient was started on the PD-L1-inhibitor avelumab, the angiogenesis inhibitor ramucirumab, and paclitaxel within the AIO-RAP trial (NCT03966118). Treatment with paclitaxel had to be stopped after 6 weeks due to further deterioration of the preexisting, FLOT-induced polyneuropathy. After initial response at 2 months lasting for a total of 4 months, computerized tomography imaging showed a progressive disease with significantly enlarged periportal lymph nodes after 6 months. The patient then received a combination of trifluridin/tipiracil and ramucirumab as third-line therapy within the AIO-ReEXPEL trial (NCT04517747) but showed a progressive disease only 2 months later.

A newly acquired tumor sample taken under treatment with ramucirumab and avelumab was sent for molecular profiling by next-generation sequencing (FoundationOne CDx – FMI) to identify potential therapeutic targets. The results showed microsatellite stability and the tumor mutations burden was not increased (5 mutations per megabase). Furthermore, the screening revealed genomic alterations in the genes of *RAD51C* and *SMARCA4*, as well as *FGF10* and *CRKL* (see Table 1). The mutation of *RAD51C* was considered to lead to deficiency of the homologous repair system, resulting in potential sensitivity to treatment with a PARPi [8]. Based on the PD-L1 positivity (CPS 20) and the HRD status, treatment with pembrolizumab and olaparib was initiated. Computerized tomography imaging initially showed a durable partial response lasting for 17 months with only a single subcutaneous new lesion, which was resected (see Fig. 1). Molecular re-profiling (FMI) of the refractory subcutaneous lesion was conducted. Table 1 displays the re-profiling of the sample which revealed a mainly identical profile with only a new loss of *FGF10*. The tumor mutations burden remained unchanged at 4 Mut/Mb. Following the FMI analysis, an immunohistochemistry staining was conducted to analyze the HER2 status and evaluate the potential for further HER2 targeting treatments. While the first staining in 2019 was negative, the new sample unexpectedly showed a positive HER2 status (IHC 3+) in 30% of tumor cells, potentially driving the progression of this lesion.

Discussion

Genomic alterations leading to HRD can be found in up to 20% of EGAs [9]. The activity of the *RAD51C* protein is regulated by *BRCA2*. A pathogenic mutation leads to a failure of the homologous repair system resulting in oncogenic genomic instability. The patient showed a durable response to the combination of pembrolizumab and olaparib. It seems unlikely that the efficacy observed is solely caused by pembrolizumab, as the patients had a tumor progression during treatment with avelumab. The efficacy of olaparib was evaluated in the phase III GOLD trial, but no significant survival benefit was observed both in the all-comers cohort as well as in the biomarker-defined cohort (patients with an *ATM* loss) [8]. The efficacy observed in this case exceeded our expectations and may be the result of a synergistic efficacy in a tumor with predictive biomarkers for both drugs (PD-L1 CPS and HRD). Notably, the combination of a PARP and PD-1/L1 inhibitor in an unselected, refractory patient population did not show high efficacy [9]. Therefore, further trials should focus on

Table 1. Molecular profiling by next-generation sequencing through FMI

Alterations	VAF % (June 21)	VAF % (June 22)
RAD51C (Protein Effect: Q332*)	52.16	56
SMARCA4 (Protein Effect: Q1196*)	61.73	65
CRKL (amplification)	Copy number (CN): 7	CN: 20
FGF10 (amplification)	CN: 18	No detection
Variants of unknown significance		
IRF4 (Protein Effect: T281T)	58.80	No detection
BTK (Protein Effect: none)	99.25	No detection
BRCA1 (Protein Effect: none)	49.46	No detection
ROS1 (Protein Effect: none)	58.21	No detection
ALK (Protein Effect: R121W)	30.38	36
NOTCH2 (Protein Effect: L2408H)	47.62	50
MLL2 (Protein Effect: L3723_Q3736del)	0.87	No detection
MLL2 (Protein Effect: R5320H)	14.62	10
MLL2 (Protein Effect: L3723_Q3735del)	31.82	44
SETD2 (Protein Effect: none)	35.54	No detection
DIS3 (Protein Effect: V121I)	38.26	21
EPHB4 (Protein Effect: R360H)	16.35	13
CREBBP (Protein Effect: S128C)	48.2	38
ETV4 (Protein Effect: none)	41.7	No detection
ERBB4 (Protein Effect: none)	74.31	No detection
ERBB3 (Protein Effect: T906S)	67.01	73.00
GNAS (Protein Effect: V245I)	43.53	39.00
KMT2A (MLL) (Protein Effect: none)	3.23	No detection
KMT2A (MLL) (Protein Effect: T2027T)	57.84	No detection
KMT2A (MLL) (Protein Effect: none)	50.00	No detection
PDGFRA (Protein Effect: none)	24.90	No detection
MSH2 (Protein Effect: none)	30.24	No detection
ETV5 (Protein Effect: none)	100.00	No detection
MED12 (Protein Effect: Q2119_Q2120insHQQQ)	99.55	100.00
INPP4B (Protein Effect: none)	62.35	No detection
PIK3C2B (Protein Effect: R458Q)	44.42	38.00
TMPRSS2 (Protein Effect: none)	83.84	No detection
JAK1 (Protein Effect: Y138Y)	45.20	Suspected Amplification (CN:7)
SGK1 (Protein Effect: none)	40.00	No detection
MAF (Protein Effect: none)	36.86	No detection
NF2 (Protein Effect: none)	1.28	No detection
FUBP1 (suspected amplification)	No detection	CN: 7

molecularly (e.g., as the patient displayed here) or clinically (platin-responders) defined subgroups. The recently started AIO POLESTAR study will provide further insight on this issue, evaluating the presented combination after response to platinum-based first-line regimen.

Acknowledgments

We would like to thank the patient for giving his consent to publish his data.

Statement of Ethics

Written informed consent was obtained from the patient for publication of this case report and any accompanying images. Ethical approval is not required for this case report in accordance with local or national guidelines.

Conflict of Interest Statement

G.M.H. and E.G. have received institutional research funding from MSD. G.M.H., E.G., and A.S. have received honorariums for advisory boards from MSD and Astra Zeneca. The other authors have no conflicts of interest to declare.

G.M.H. received fees for an advisory role from Bristol-Myers Squibb, MSD Sharp and Dohme, Lilly, Novartis, Daiichi Sankyo. He received speaker's honoraria from Servier, MSD Sharp and Dohme, Lilly, Targos, Bristol-Myers Squibb, Iomedico, and MCI conventions. Funding for investigator-initiated research projects was provided by Nordic Pharma, Taiho Pharmaceutical, MSD Sharp and Dohme. Travel and Accommodations were provided by Bristol-Myers Squibb, Lilly, Servier, MSD Sharp and Dohme.

Funding Sources

There was no funding for this case report.

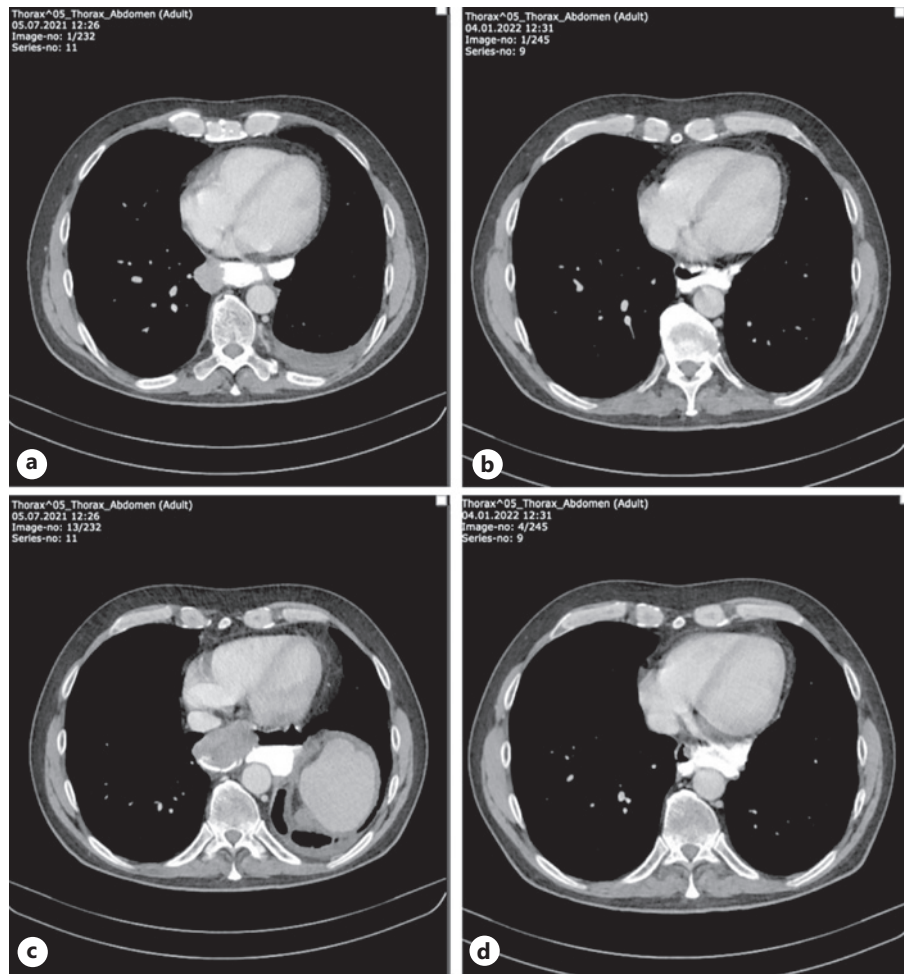


Fig. 1. CT imaging of the patient before and after treatment with Pembrolizumab and Olaparib. **a, c** July 2021: the patient shows a tumor burden in the posterior mediastinum with enlarged paravertebral lymph nodes. **b, d** January 2022: notable decrease of the tumor mass within the mediastinum but also the paravertebral lymph nodes.

Author Contributions

Conception, design, and collection of data: J.C.A. and A.S. Data analysis, interpretation, manuscript writing, and final approval: J.C.A., J.T., G.M.H., E.G., J.S., and A.S.

Data Availability Statement

All data generated or analyzed during this study are included in this article. Further inquiries can be directed to the corresponding author.

References

- Sung H, Ferlay J, Siegel RL, Laversanne M, Soerjomataram I, Jemal A, et al. Global cancer statistics 2020: GLOBOCAN estimates of incidence and mortality worldwide for 36 cancers in 185 countries. *CA Cancer J Clin.* 2021; 71(3):209–49.
- Janjigian YY, Shitara K, Moehler M, Garrido M, Salman P, Shen L, et al. First-line nivolumab plus chemotherapy versus chemotherapy alone for advanced gastric, gastro-oesophageal junction, and oesophageal adenocarcinoma (CheckMate 649): a randomised, open-label, phase 3 trial. *Lancet.* 2021; 398(10294):27–40.
- Obermannová R, Alsina M, Cervantes A, Leong T, Lordick F, Nilsson M, et al. Oesophageal cancer: ESMO Clinical Practice Guideline for diagnosis, treatment and follow-up. *Ann Oncol.* 2022;33(10): 992–1004.
- Fuchs CS, Tomasek J, Yong CJ, Dumitru F, Passalacqua R, Goswami C, et al. Ramucirumab monotherapy for previously treated advanced gastric or gastro-oesophageal junction adenocarcinoma (REGARD): an international, randomised, multicentre, placebo-controlled, phase 3 trial. *Lancet.* 2014;383(9911):31–9.
- Kang YK, Boku N, Satoh T, Ryu MH, Chao Y, Kato K, et al. Nivolumab in patients with advanced gastric or gastro-oesophageal junction cancer refractory to, or intolerant of, at least two previous chemotherapy regimens (ONO-4538-12, ATTRACTION-2): a randomised, double-blind, placebo-controlled, phase 3 trial. *Lancet.* 2017;390(10111): 2461–71.
- Fuchs CS, Doi T, Jang RW, Muro K, Satoh T, Machado M, et al. Safety and efficacy of pembrolizumab monotherapy in patients with previously treated advanced gastric and gastro-oesophageal junction cancer: phase 2 clinical KEYNOTE-059 trial. *JAMA Oncol.* 2018;4(5): e180013.

- 7 Bang YJ, Im SA, Lee KW, Cho JY, Song EK, Lee KH, et al. Randomized, double-blind phase II trial with prospective classification by ATM protein level to evaluate the efficacy and tolerability of olaparib plus paclitaxel in patients with recurrent or metastatic gastric cancer. *J Clin Oncol*. 2015;33(33):3858–65.
- 8 Bang YJ, Xu RH, Chin K, Lee KW, Park SH, Rha SY, et al. Olaparib in combination with paclitaxel in patients with advanced gastric cancer who have progressed following first-line therapy (GOLD): a double-blind, randomised, placebo-controlled, phase 3 trial. *Lancet Oncol*. 2017;18(12):1637–51.
- 9 Riaz N, Blecua P, Lim RS, Shen R, Higginson DS, Weinhold N, et al. Pan-cancer analysis of bi-allelic alterations in homologous recombination. DNA repair genes. *Nat Commun*. 2017;8(1):857.